Critical decisions in emergency medicine

Volume 33 Number 3 **March 2019**

Force of Nature

A growing number of adventure-seekers are departing their urban confines to explore the great outdoors. As such, clinicians must be prepared to initiate life- and limb-saving treatment for wilderness-related injuries, even in the most challenging of environments. Proper planning and appropriate interventions can greatly affect the outcomes of these patients, both in the field and in the emergency department.

Buckled Up

While there's no question that seat belts save lives and reduce the severity of trauma caused by motor vehicle accidents, there are a number of serious injuries that can be inflicted by the restraint itself. Despite the ever-increasing number of safety features used by modern car manufacturers, children remain at particular risk for seat belt–associated trauma, including unique injuries to the abdomen and spine.

THE OFFICIAL CME PUBLICATION OF THE AMERICAN COLLEGE OF EMERGENCY PHYSICIANS

Force of Nature

Trauma in the Wilderness

LESSON 6


By **Andrew Park, DO, MPH;** and **Thomas Seibert, MD, MS**

Dr. Park is a fellow of the Wilderness Medical Society and an assistant professor in the Department of Emergency Medicine at the University of Kansas Medical Center in Kansas City, Missouri. Dr. Seibert is a fellow of the Wilderness Medical Society and a wilderness medicine fellow at the University of Utah in Salt Lake City.

Reviewed by **Nathaniel Mann, MD**

OBJECTIVES

On completion of this lesson, you should be able to:

1. Identify the most common traumatic injuries sustained in wilderness settings.
2. Decide when to perform an emergent needle decompression of the chest in the field.
3. Describe the factors to consider in evacuations.
4. Determine the appropriate use of orthopedic reductions.
5. Determine the appropriate use of tourniquets.

FROM THE EM MODEL

18.0 Traumatic Disorders

CRITICAL DECISIONS

- How should a patient be evaluated after a traumatic event in the wilderness?
- When should needle decompression of the chest be performed in the field?
- When should a patient be treated in place versus being evacuated to definitive care?
- When should an orthopedic fracture or dislocation be reduced in the wilderness?
- What factors should be considered before applying a tourniquet?

A growing number of adventure-seekers are departing their urban confines to explore the great outdoors. As such, clinicians must be prepared to initiate life- and limb-saving treatments for wilderness-related injuries, even in the most austere environments and with limited resources and manpower.[1,2] Proper planning and appropriate interventions can greatly affect outcomes, both in the field and in the emergency department. In light of the rising global interest in outdoor activities, it is increasingly important for clinicians to understand how to prevent, evaluate, and manage the traumatic injuries they are most likely to encounter as expedition medical officers, guides, trip leaders, or participants.

CASE PRESENTATIONS

CASE ONE

A 23-year-old musher and his dog team are making good time on the Iditarod Trail in Alaska. As the trail turns away from the river and into a wooded area, the musher's sled slides off the edge of a thin snow bridge, propelling him onto the end of a large branch. An emergency physician and his friend discover the musher while following the race on snow machines. The physician finds the man awake and alert but bent over with labored breathing.

On examination, the musher has a heart rate of 120 with good distal perfusion, right chest wall tenderness, distended neck veins, and a slight tracheal deviation to the left. His mental status is good, but he is in pain. The nearest hospital is approximately 80 miles away, and there is no road access.

CASE TWO

A 50-year-old rock climber falls to the ground after her camming device fails. Her frantic climbing partner summons help from a group of hikers, which includes an emergency physician, who rushes to the scene. The climber's airway and breathing are intact, but she is lying on the ground in obvious distress. Her right leg appears shortened compared to the left and is held in external rotation. Her left leg has a visible deformity just above the knee.

The patient's pulse is 130, her respiration rate is 24, and she feels euthermic. An examination of her head, neck, arms, and torso are unremarkable, and her Glasgow Coma Scale (GCS) score is 15. She is moving both arms and has 2+/4 bilateral radial pulses. The physician removes the patient's climbing shoes to measure her lower-extremity pulses, which are 2+/4 in the right foot but weakly palpable in the left foot. Additionally, the left foot and calf feel cooler to the touch than the right leg. Her sensation to light touch is intact and symmetrical in all bilateral lower dermatomes.

The physician's backpack contains a small first-aid kit with oral over-the-counter medications, hiking poles, duct tape, a multi-tool, and an emergency locator GPS system. The climbers have rope and small packs with snacks and water. The group is 4 miles from the trailhead, which is 2,200 feet lower in altitude, and there is no cell phone reception.

CASE THREE

A mountain biker loses control on a tight turn and is thrown off the trail into a pile of rocks. As others slow oncoming cyclists, one of the riders, an emergency physician, approaches and sees blood dripping from the patient's sleeve at a concerning rate. The bicyclist is able to speak in full sentences and remembers the accident. He denies shortness of breath, and the physician notes an equal rise and fall of the chest. The patient's radial pulse bilaterally is 2+/4, and he is tachycardic. His GCS score is 15, and he is moving all extremities without difficulty. He was wearing a helmet and has no deformities or signs of other injuries.

The physician cuts open the patient's sleeve to reveal a deep puncture wound and laceration to the anterior aspect of the proximal forearm. Brisk, bright red blood is pulsating out. Re-examination distally reveals an intact radial pulse and sufficient capillary refill. As pressure is applied to the wound, a medical history is taken, which reveals no significant medical problems, no surgeries, and no allergies.

Collectively, the cyclists are carrying a moderate amount of first-aid supplies, oral pain control, bike repair kits, water, and cell phones. The group is 2 miles from the parking lot, so one of the riders bikes out to the trailhead while another contacts 911 and confirms that EMS is en route. Despite the application of direct pressure, the wound is still bleeding around the bandage after 15 minutes. The patient thinks he can walk but is feeling weak.

The distribution of death from trauma is trimodal in nature. The first fatalities, which occur within the first few minutes of the event, usually arise from catastrophic injuries (eg, aortic rupture, high spinal cord injuries). The second peak of fatalities occurs in the first few hours and is usually associated with intracranial injuries, pneumothoraces, and hemorrhagic anemia. The third peak is delayed for days to weeks, likely secondary to infection or other complications. The term "golden hour" in trauma literature is used to describe the second peak of fatalities, which can be greatly reduced with proper assessment and treatment. In the wilderness setting, however, it is unlikely that the victim will arrive at a trauma center within the "golden hour."[3]

From 2007 to 2011, the US National Park System reported an average of 280 million annual visits. An estimated 32.5 out of every 1 million visitors require a trauma or first-aid evaluation.[4] Although this frequency is low, it equates to 9,076 annual incidents.[4] One study suggests that as many as 80% of these fatalities occur prior to evacuation.[5]

CRITICAL DECISION

How should a patient be evaluated after a traumatic event in the wilderness?

Researchers have described applying the "golden principles" of prehospital trauma care in the urban setting. Although these guidelines were not intended for use in wilderness medicine, several key components are applicable to outdoor settings. Rescuers should continually evaluate the safety of both the patient and the provider; employ primary and secondary surveys; ensure

cervical spine immobilization (*Figure 1*); address external hemorrhage; keep the patient warm; initiate early evacuation; and, above all, do no harm.[3]

Once the patient is in the safest, most stable environment possible, the Advanced Trauma Life Support (ATLS)–based steps of trauma management should be implemented, as adapted for the outdoors:[6]

1. Primary survey
2. Resuscitation
3. Secondary survey
4. Definitive plan
5. Packaging and transfer preparation

Even in the wilderness, the primary survey should employ the ABCDEs of any trauma evaluation:[6]

- **A**irway maintenance and cervical spine stabilization
- **B**reathing
- **C**irculation and control of significant external hemorrhage
- **D**isability: neurological status
- **E**xposure/environmental control

Following the primary survey, the patient should be resuscitated with the available equipment and supplies. Next, a secondary survey should be performed to evaluate the patient from head to toe. When appropriate, it is important to completely undress the patient and examine all aspects of the body for signs of injury. In some environments, however, full exposure can lead to hypothermia and further complications. In potentially dangerous locations, a full examination may be impossible. In such cases, physicians should minimize exposure to the elements and use auscultation and palpation to evaluate the patient.

A thorough medical history should also be taken, using the AMPLE pneumonic (**A**llergies, **M**edications, **P**ast medical history, **L**ast meal, **E**vents leading to injury) from the ATLS guidelines.[6] The history and physical examination can be used to generate a list of injuries and discern which, if any, require immediate intervention or evacuation. In addition, factors such as the severity of the trauma, possible methods of evacuation, and potential routes must be weighed.

When managing chest trauma, for example, the most serious complications should be considered first, including pneumothorax, tension pneumothorax, flail chest, and cardiac tamponade. A traumatic aortic dissection or rupture is likely to be fatal before interventions can be employed. A patient with chest trauma also must be evaluated for shortness of breath, tachycardia, and altered mental status, which can signal hypoxia. In these situations, a handheld pulse oximeter can be invaluable.

The chest should then be examined for major deformities, symmetry, and other signs of trauma, including tenderness with palpation and skin damage or changes. An uneven chest wall rise, however subtle, is a pathognomonic sign of flail chest secondary to multiple rib fractures. A deviated trachea away from the side of injury, tachycardia, distended neck veins, and increased work of breathing or hypoxia are all signs of a tension pneumothorax. Altered mental status may be present in cases of severe or prolonged hypoxia or significant blood loss from severe chest trauma, with or without concomitant injuries.

FIGURE 1. Wilderness Medical Society Focused Spine Assessment

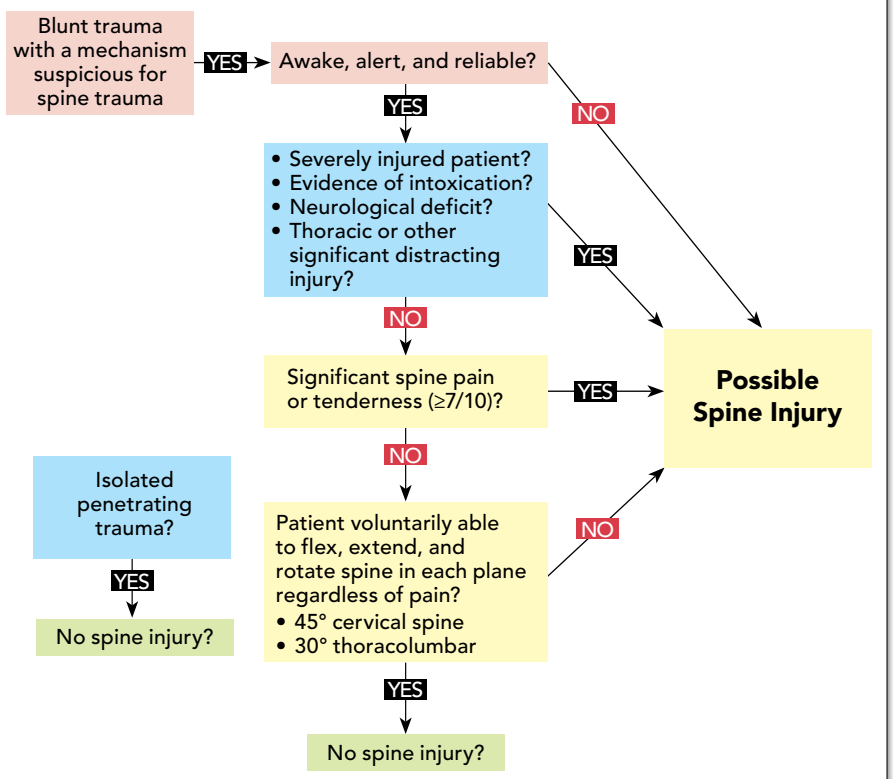

CRITICAL DECISION

When should needle decompression of the chest be performed in the field?

Patients with severe symptoms following chest trauma must be evaluated for life-threatening injuries, including a pneumothorax or tension pneumothorax. Patients with a suspected pneumothorax should be transported as quickly as possible to the nearest medical facility for further evaluation and definitive treatment. Any patient without severe symptoms should be monitored for signs and symptoms of an expanding pneumothorax and a subsequent tension pneumothorax.

The pathophysiology of a tension pneumothorax includes the development of a one-way valve secondary to the injured lung tissue, which allows air to enter and expand the pleural space. Because the air is unable to escape and volume expansion is limited, the pressure in

FIGURE 2. Pain Treatment Pyramid

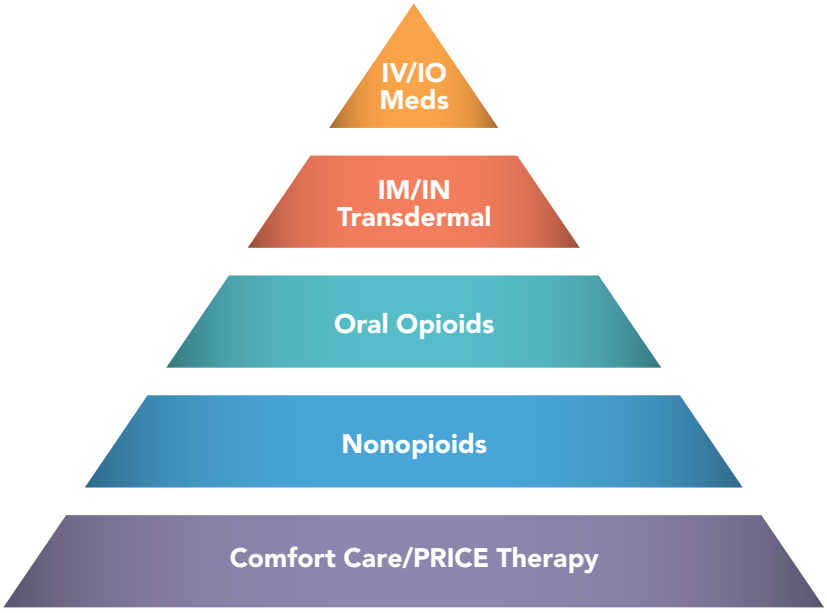

PRICE: Protection, Rest, Ice, Compression, Elevation

IM: Intramuscular IN: Intranasal IV: Intravenous IO: Intraosseous

Adapted from the Wilderness Medical Society Practice Guidelines for the Treatment of Acute Pain in Remote Environments.

the injured hemithorax increases. The lung on the affected side collapses, and the increased pressure displaces the mediastinum contralaterally, resulting in compression of the superior and inferior venae cavae. These events subsequently affect venous return and reduce preload, prompting signs and symptoms of shock. Indications for immediate needle decompression in a patient with chest trauma in the wilderness include:

- Significant shortness of breath
- Hypoxia or cyanosis
- Distended neck veins
- Tracheal deviation
- Altered mental status

Once a tension pneumothorax has been identified, the severity of the injury and the next steps should be discussed. If help is available, someone else should arrange for emergent evacuation while the physician explains the importance of needle decompression to the patient. It is important to emphasize that the procedure is a potentially lifesaving therapy for a tension pneumothorax, a condition that can rapidly lead to cardiovascular collapse and death if left untreated.

When managing a patient in the wilderness setting, it is always important to minimize exposure and alleviate pain as much as possible (*Figure 2*). As in the hospital setting, once the needle decompression has been performed, the catheter should be secured in place. While preventing entanglement, the patient should be reclothed to prevent further exposure. Frequent reassessments should be performed to look for signs of decompensation and reaccumulation of the pneumothorax.

CRITICAL DECISION

When should a patient be treated in place versus being evacuated to definitive care?

Patients who become sick or injured in the wilderness must be quickly evaluated, and a determination must be made as to whether they can be managed on-site or must be evacuated for definitive treatment (*Figure 3*). Patients who are at risk of significant complications or death require urgent evacuation. Nonurgent evacuation can be considered for those who need further evaluation and treatment but are at low risk of rapid decompensation or death.

This determination should be made with the help of everyone in the group, including the patient, if possible. It is imperative for medical or rescue leaders to:

- understand the capability of the group and the experience of its members;
- know the capability of any local rescue organizations and how to contact them; and
- consider the geographical area and the timing necessary for an evacuation.

Rescue leaders should also develop a coordinated plan that is communicated to at least one person not involved in the trip. An awareness of these limitations can help to more clearly define when such decisions must be made.

After a trauma evaluation, the clinician must determine whether the patient's injury can be definitively treated in the field with the supplies available or whether the injury, if not managed urgently, could worsen significantly. These decisions can be much easier to make when assessing injuries at each end of the severity spectrum. For example, patients with minor wounds can often be treated in the field and released to continue their journey.

Paul Auerbach's authoritative *Wilderness Medicine* describes which patients require evacuation, including:[7]

1. Those who do not improve or deteriorate after treatment
2. Those with debilitating pain
3. Those with an inability to sustain travel at a reasonable pace due to a medical problem
4. Those with persistent abdominal pain
5. Those with signs and symptoms of serious high-altitude illness
6. Those with infections that do not improve after 24 hours of treatment
7. Those with chest pain not clearly from a minor musculoskeletal injury

8. Those who develop a psychiatric issue that puts the patient or the group at risk
9. Those with large or serious injuries or wounds with complications (eg, an open fracture, fractures with deformity, fractures with impaired neurovascular status, gunshot wounds, a suspected spinal cord injury, and certain burns)

Travel toward definitive medical care can continue in scenarios 3, 4, and 8, or when descending in scenario 5. Evacuating a patient from a wilderness setting requires relaying important factors to EMS and search and rescue (SAR) personnel, including a description of the patient's injuries, the treatment given, the environmental conditions, and the type of evacuation required. Evacuation is a time- and personnel-intensive task that often moves more slowly than 1 mile per hour, depending on the injury, terrain, and supplies.

Patients who are severely ill or have sustained an injury with a high risk of morbidity or mortality necessitate both on-site treatment and timely evacuation. Any urgent medical needs must be addressed on-site while evacuation is simultaneously arranged.

CRITICAL DECISION

When should an orthopedic fracture or dislocation be reduced in the wilderness?

Musculoskeletal trauma accounts for approximately 80% of wilderness-related accidents. Ankle fractures are the most commonly encountered injuries in the outdoor setting. Without immediate access to radiographs, a detailed history can help properly diagnose orthopedic trauma. The patient may be able to describe force vectors that led to the injury or state whether a "pop" was heard. After the primary survey and a focused evaluation of the spine and pelvis, the clinician should concentrate on focal extremity injuries.[8] It is paramount to evaluate for deformities, crepitus, swelling, skin changes, and neurovascular function. When uncertain, the injured limb should be compared to the unaffected side.

Any dislocation that appears to be an isolated injury can and should be reduced on scene if the procedure can be accomplished safely. Early reductions are usually easier, when swelling and muscle spasms are less severe. In addition, early intervention can significantly reduce pain and mitigate the need for evacuation. If a fracture is associated with the dislocation, a reduction is less likely to be successful and is therefore discouraged. Techniques for reduction depend on the treating clinician, affected joint, and medicines available. Reductions of the fingers and patellae can often be completed without any anesthesia. Ankles and shoulders can benefit from intra-articular, intramuscular, or oral pain control or anesthesia. A dislocated hip or knee is a major injury that may not be reducible without sedation; in such cases, transport may be required.[7]

As in the emergency department, patients who require an urgent reduction in the wilderness include those with decreased perfusion distally, those with reduced neurological function distally, and those at risk of developing compartment syndrome. Traditionally, large deformities without these concerns were reduced and placed in external traction splints; however, this approach is no longer recommended. The Wilderness Medical Society practice guidelines discourage the routine use of traction splints on long-bone fractures (stereotypically femurs). Initially, in-line traction can provide relief; however, prolonged external traction devices or improvisations can lead to skin necrosis and reduced circulation, and have no proven benefit.[8]

FIGURE 3. Evacuation Plan Flowchart

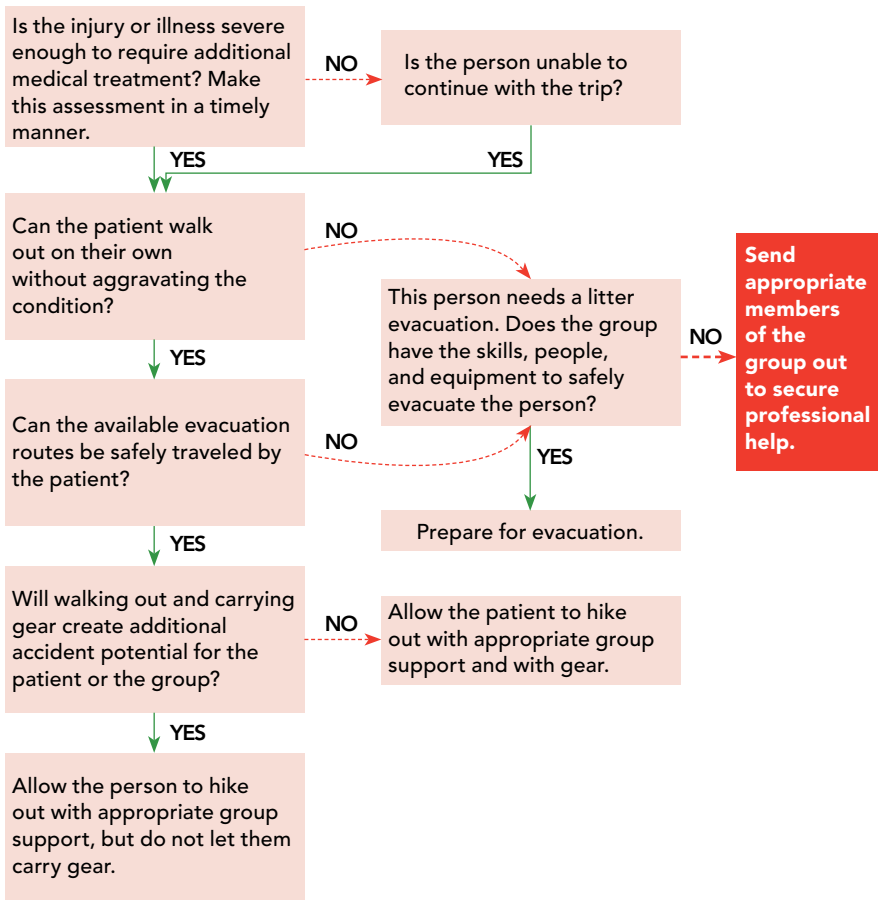

Pearls

- Patients with chest wounds, extreme dyspnea, loss of unilateral breath sounds, or signs of a tension pneumothorax require an immediate needle decompression of the chest.
- Patients who have signs of acute blood loss, altered mental status, a life-threatening condition, or progressively worsening symptoms should be evacuated as quickly as possible.
- Patients with a loss of pulses or feeling in a fractured or dislocated extremity should undergo emergent reduction of the affected limb.
- A tourniquet should be applied to stop bleeding that fails to respond to the application of direct pressure.

CRITICAL DECISION

What factors should be considered before applying a tourniquet?

Hemorrhagic shock is the leading cause of death on the military battlefield and is the second leading cause of traumatic deaths in the civilian sector. Because of this risk — which is inherent in any low-resource environment, including the wilderness — the United States Armed Forces developed the MARCH mnemonic to direct the initial assessment of soldiers injured during combat operations:

- **M**assive hemorrhage
- **A**irway
- **R**espirations
- **C**irculation
- **H**ead injuries/hypothermia

This battlefield protocol has been successfully employed in wilderness sectors. Applying a tourniquet before a victim goes into shock appears to provide a profound survival benefit (96% vs 4%). Prehospital application vs hospital application also appears to improve the likelihood of survival (89% vs 78%, $p < 0.05$).[9]

There appears to be no correlation between morbidity and the time a tourniquet stays in place, and no increase in thromboembolic events, necrosis, amputation, or renal failure. Research also shows a slight, but statistically significant, increase in the need for a fasciotomy if the tourniquet remains in place for more than 2 hours; however, 91% of tourniquets in the referenced study were removed prior to the 2-hour mark.[10]

One of the biggest mistakes a clinician can make when applying a tourniquet in the prehospital setting is failing to tighten it enough. An estimated 83% of extremities have palpable distal pulses upon hospital arrival, which can lead to a "venous tourniquet" that increases the risk of compartment syndrome or increased blood loss by allowing inflow while precluding a return to systemic circulation from the injured limb.[11,12]

Tourniquets are a safe and effective way to treat wounds with significant bleeding. If direct pressure is ineffective, the next step should be the application of a tourniquet proximal to the wound, which should be tightened until the distal pulses are occluded.

Summary

It is imperative for emergency physicians to recognize how proper planning, evaluation, and treatment can greatly affect the outcomes of patients who have been injured in wilderness settings. A timely trauma survey can help differentiate between minor injuries and those that require immediate life- or limb-saving treatment.

The timely identification of a tension pneumothorax is critical when managing patients with chest trauma. Such cases mandate immediate needle decompression of the chest followed by emergent evacuation to the nearest medical facility. Patients with fractures or dislocations that compromise the distal tissues, or those with other complicating factors such as evacuation times, require emergent reduction of the affected limb to prevent further morbidity.

Penetrating trauma to the extremities with uncontrolled blood loss puts patients at grave risk for hypovolemic shock and death; in these situations, tourniquets must be applied promptly and properly. Clinicians must also be prepared to weigh a variety of environment-specific factors when devising a treatment plan and determining the need for evacuation.

REFERENCES

1. National Center for Injury Prevention and Control. Ten leading causes of death and injury. Centers for Disease Control and Prevention website. http://www.cdc.gov/injury/wisqars/leadingcauses.html. Published February 25, 2016. Accessed November 20, 2016.

Pitfalls

- Failing to prepare for the most common injuries encountered in the wilderness or for specific types of travel, an oversight that can adversely impact a physician's ability to effectively respond to emergencies in the field.
- Waiting too long to reduce a fracture or dislocation. Delays can make the reduction of the affected limb more difficult due to increased muscle spasms and swelling around the wound. Delaying reduction can also adversely affect the tissue distally.
- Using improper techniques or equipment, including external traction splints, which are no longer recommended.
- Failing to adapt emergency procedures to the outdoor setting, which can lead to complications and death.
- Neglecting to recognize when an emergent evacuation is warranted, a mistake that can increase morbidity and mortality.

CASE RESOLUTIONS

CASE ONE

Within minutes, the musher became tachycardic and dyspneic. The initial trauma survey revealed a chest wound accompanied by shortness of breath and absent breath sounds on the right side. Because the musher also had distended neck veins and a tracheal deviation to the left, the physician suspected a tension pneumothorax, a life-threatening injury that requires immediate needle decompression to prevent further cardiovascular decompensation and death. As the patient's symptoms worsened, treating the tension pneumothorax became paramount.

While the physician discussed the urgency of the injuries with the patient, the friend called for immediate evacuation to the nearest medical facility and provided their coordinates. The physician performed a needle decompression of the chest and heard a rush of air from the musher's chest. Pain medicine was administered (800 mg of ibuprofen and 1 g of acetaminophen by mouth), and the patient was re-evaluated frequently to assess for pain, clinical stability, and comfort. The physician instructed the musher to slide into his sled to stay out of the wind, as the group sheltered in the wooded area.

Approximately 45 minutes later, a rescue helicopter landed on the frozen river, and the flight medic signaled that he was ready for the patient. The physician relayed to the flight crew that the catheter used to decompress the patient's chest was still in place. The pilot stated he would fly low to reduce the chance of re-expansion secondary to decreased barometric pressure at higher altitude. On arrival at the medical center, a chest tube was placed, and the patient was admitted for further observation.

CASE TWO

The physician suspected that the fallen rock climber had sustained a right hip fracture and/or dislocation and a left distal femur fracture with significant displacement, which was contributing to vascular compromise distally. No additional injuries were found. The skin was intact, and no signs of external hemorrhage existed.

Because of decreased perfusion, the physician focused on the left leg first. He administered ibuprofen (800 mg) and acetaminophen (1 g) orally and applied gentle in-line traction, which initially caused significant pain but led to improved comfort. Reassessment of the leg revealed improvement in the visible deformity and a 2+/4 dorsalis pedis pulse. The warmth and color of the leg improved.

The physician was unsure if the woman's right leg was fractured or dislocated but did not believe she had an open-book pelvic fracture. Concerned about how painful a reduction attempt would be given the lack of pharmacological supplies and the inability to determine concomitant pelvic or femur fractures, he deferred intervention; splinted the legs together with the knees in slight flexion, with padding between the thighs and in the popliteal fossae; and then confirmed that the patient was still neurovascularly intact.

The physician indicated an emergency on the GPS locator, and the group waited nearly 4 hours for the SAR team to appear. A paramedic administered fentanyl intramuscularly (100 mcg). The patient was then placed in a vacuum litter, fitted with a cervical collar, and packaged into a one-wheeled litter. It took 8 hours to reach the ambulance at the trailhead. At the local hospital, the patient was diagnosed with a right hip dislocation and a left distal femur fracture. With procedural sedation, the hip was reduced, and she was admitted for surgical repair of the left femur.

CASE THREE

The physician fashioned a wide tourniquet from a spare bike tube and a sturdy branch, which was placed 4 inches proximal to the cyclist's wound. Twisting the branch increased the tension and eventually occluded the radial pulse. When the bleeding abated, the physician changed the dressing and applied a pressure dressing directly to the wound.

Pain medication and oral fluids were given. With assistance, the patient ambulated slowly toward the trailhead. The group was met by EMS, who established an IV and transferred the patient to the local hospital. CT angiography showed a laceration to the proximal ulnar artery. The patient underwent urgent vascular repair and was discharged in stable condition a few days later.

2. Hubbell FR. Wilderness emergency medical services and response systems. In: Auerbach PS, ed. *Wilderness Medicine*. 5th ed. Philadelphia, PA: Mosby Elsevier; 2007:694-707.
3. Collier BR, Riordan PR Jr, Nagy JR, Morris JA Jr. Wilderness trauma, surgical emergencies, and wound management. In: Auerbach PS, ed. *Wilderness Medicine*. 5th ed. Philadelphia, PA: Mosby Elsevier; 2007:475-504.
4. Declerck MP, Atterton LM, Seibert T, Cushing TA. A review of emergency medical services events in US national parks from 2007 to 2011. *Wilderness Environ Med*. 2013 Sep;24(3):195-202.
5. Goodman T, Iserson KV, Strich H. Wilderness mortalities: a 13-year experience. *Ann Emerg Med*. 2001 Mar;37(3):279-283.
6. American College of Surgeons Committee on Trauma. *ATLS: Advanced Trauma Life Support for Doctors*. 8th ed. Chicago, IL: American College of Surgeons; 2008:2-11.
7. Switzer JA, Ellis TJ, Swiontkowski MF. Wilderness orthopedics. In: Auerbach PS, ed. *Wilderness Medicine*. 5th ed. Philadelphia, PA: Mosby Elsevier; 2007:573-603.
8. Forgey WW; Wilderness Medical Society. *Wilderness Medical Society: Practice Guidelines for Wilderness Emergency Care*. 5th ed. Guilford, CT: Morris Book Publishing; 2006.
9. Kragh JF Jr, Littrel ML, Jones JA, et al. Battle casualty survival with emergency tourniquet use to stop limb bleeding. *J Emerg Med*. 2011 Dec;41(6):590-597.
10. Kragh JF Jr, Walters TJ, Baer DG, et al. Practical use of emergency tourniquets to stop bleeding in major limb trauma. *J Trauma*. 2008 Feb;64 (2 Suppl):S38-S50.
11. King DR, van der Wilden G, Kragh JF Jr, Blackbourne LH. Forward assessment of 79 prehospital battlefield tourniquets used in the current war. *J Spec Oper Med*. 2012 Winter;12(4):33-38.
12. Drew B, Bennett BL, Littlejohn L. Application of current hemorrhage control techniques for backcountry care: part one, tourniquets and hemorrhage control adjuncts. *Wilderness Environ Med*. 2015 Jun;26(2):236-245.